

Shoulder Health after SCI: Medical Intervention & Prevention

Authors: Meegan Van Straaten, PT, MSPH; Beth Cloud, PT, DPT, PhD; Kristin Zhao, PhD; Missy Morrow, PhD

Fact Sheet

Produced by



a Special Interest Group of



Contact us:

ANPT
5841 Cedar Lake Rd S.
Ste 204
Minneapolis, MN 55416
Phone: 952.646.2038
Fax: 952.545.6073
info@neuropt.org
www.neuropt.org

a component of



Some examples of conservative treatment methods which could be used first can be seen in Chart 1. If these conservative treatment methods do not work, however, additional medical interventions (like those listed in Chart 2 and described further below) may be required.

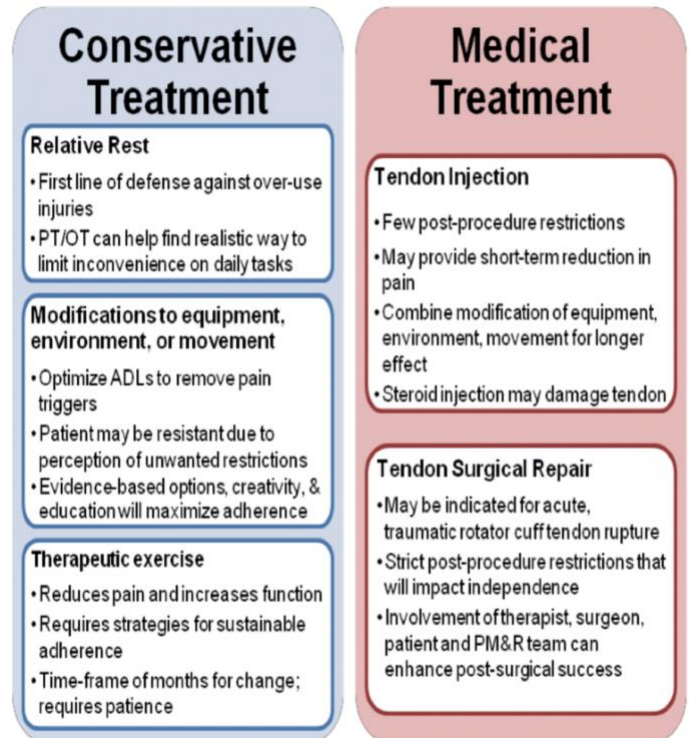


Chart 1

Chart 2

What options exist if conservative treatment is not enough?

Steroid injection to the tendon:

An injection of anti-inflammatory corticosteroid medication may provide short term relief of pain from rotator cuff disease but should not be used in isolation since it does not treat the underlying cause of pathology. Its effectiveness may be optimized when administered under ultrasound (US) guidance for accurate needle positioning,¹ and this method may result in less post-procedure pain. Post-procedure restrictions require a few days of reduced use of the arm. Steroid injection use requires careful consideration because of the steroids' secondary harm to the tendon.² There are mixed opinions among providers on the appropriateness of steroid injections in the SCI patient due to the tendon damage that an already heavily loaded tendon may not tolerate.

Surgical repair of torn tendons:

While surgical repair for acute, traumatic rotator cuff rupture may be required, there are no clear guidelines for the timing of repair for degenerative and overuse tendon tears (Figure). Determining which partial tears will progress is often unpredictable, and pathological findings don't always align with clinical symptoms.³ Conservative treatment is almost always prescribed first for the nonacute tear; however, surgical repair may no longer be possible after significant muscle atrophy and fatty infiltration, so intervening early with surgery may have benefits. Surgical procedures continue to require total immobilization and disuse of the upper extremity for 6-8 weeks following the procedure. Active assistive range of motion is allowed at the 6-8 week time

Produced by



a Special Interest Group of



Contact us:

ANPT
5841 Cedar Lake Rd S.
Ste 204
Minneapolis, MN 55416
Phone: 952.646.2038
Fax: 952.545.6073
info@neuropt.org
www.neuropt.org

a component of



point, but aggressive strengthening is not prescribed until 6 months post-operatively. Surgical outcome studies in the SCI population are extremely limited; however, Fattel et al. (2014) reported successful outcomes following rotator cuff surgery utilizing a multidisciplinary team approach.⁴ Involvement of the therapist, surgeon, patient and PM&R team all acting in the decision-making process was a key contributor to the post-surgical success.

Invasive treatment options for rotator cuff injuries are often limited for the SCI population, due to dependence on their upper extremities, difficulty adhering to post-treatment load/motion restrictions, and due to the drawbacks of the treatments themselves, including the recurrence/failure rates of the treatments. Fortunately, a strong shoulder with proper alignment and good balance of opposing muscles can often be quite functional and pain-free even in the presence of rotator cuff non-reversible pathology.

Prevention

To prevent and heal over-use injuries in the shoulder, the importance of rest should not be underestimated. Seemingly difficult to implement in the SCI population, resting the shoulder may be under-appreciated. Rest does not necessarily mean disuse of the upper extremity, but rather a relative reduction of stress on the shoulder or breaks implemented during repetitive tasks such as manual wheelchair propulsion.⁵ ADLs and other aspects of the regular routine should not feel overly strenuous or cause pain to the shoulder. If they do, a temporary solution to reduce the stress should be considered. Working with the patient to determine realistic solutions may include reassessing wheelchair fit and activities of daily living.

We recommend that you review “Preservation of Upper Limb Function following Spinal Cord Injury” (2005) <https://pva.org/research-resources/publications/clinical-practice-guidelines/> for recommendations⁶ such as:

- Wheelchair construction and fitting recommendations
- Recommended manual propulsion movement patterns such as:
 - Encouraging the wheelchair user to use long, smooth push strokes
 - Encouraging a “semicircular or oval” spatial push pattern for better shoulder biomechanics and reduction of shoulder position compromise
- Adjustments to reduce or prevent shoulder overuse and injury such as:
 - Adjusting the rear axle as far forward as possible without compromising stability for more efficient propulsion
 - Adjustments so that when the hand is placed at top dead-center on the pushrim, the angle between the upper arm and forearm is between 100- 120 degrees

References:

1. Finnoff JT, Hall MM, Adams E, Berkoff D, Concoff AL, Dexter W et al. American Medical Society for Sports Medicine (AMSSM) position statement: interventional musculoskeletal ultrasound in sports medicine. *British Journal of Sports Medicine* 2015;49(3):145-50.
2. Coombes BK, Bisset L, Vicenzino B. Efficacy and safety of corticosteroid injections and other injections for management of tendinopathy: a systematic review of randomised controlled trials. *Lancet* 2010;376(9754):1751-67.
3. Rudzki JR, Shaffer B. New approaches to diagnosis and arthroscopic management of partial-thickness cuff tears. *Clin Sports Med* 2008;27(4):691-717.
4. Fattel C, Coulet B, Gelis A, Rouays-Mabit H, Verollet C, Mauri C et al. Rotator cuff surgery in persons with spinal cord injury: relevance of a multidisciplinary approach. *Journal of Shoulder & Elbow Surgery* 2014;23(9):1263-71.
5. Van Straaten MG, Cloud BA, Zhao KD, Fortune E, Morrow MMB. Maintaining shoulder health after spinal cord injury: A guide to understanding treatments for should pain. *Arch Phy Med Rehab* 2017;98:1061-3.
6. Boninger ML et al. (Paralyzed Veterans of America Consortium for Spinal Cord Medicine). Preservation of upper limb function following spinal cord injury. *J Spinal Cord Med* 2005;28(5):434-470.