

Active Range of Motion of the Cervical Spine

Description

Active ROM assessment is performed by asking the client to actively contract the neck muscles in all six different cardinal range of motion. The six-cardinal ROM in three planes are as follows:

- Sagittal plane: flexion and extension
- Frontal plane: right lateral flexion and left lateral flexion
- Transverse plane: right rotation and left rotation

Different Causes of Restricted/Limited Motion

- Pain/spasm
- Stiffness
- Ligament/Joint injury
- Fear Avoidance

Presence of Pain During Active Range of Motion

If pain is present with active ROM, the assessment is considered positive. The presence of pain indicates that three possible circumstances exist:

- The “mover” muscles that are contracting to create the motion are strained, causing the client to experience pain when contracting them.
- The ligaments and joint injury causing the patient to feel pain when there is a movement.
- The (antagonist) muscles on the other side of the joint from the direction of motion performed are strained and/or spasmed, causing the client to feel pain when these muscles are stretched.

One or any combination of these conditions can exist.

Conversely, if no pain is present, then the client does not have any of these conditions.


ANPT Concussion/mTBI Knowledge Translation Task force

Handout Created by:

Naseem Chatiwala, PT, DPT, MS; Annie Fangman, PT, DPT; Michelle Gutierrez, PT, DSc; John Heick, PT, DPT, PhD; Ethan Hood, PT, DPT, MBA; Victoria Kochick, PT, DPT; Becky Bliss, PT, DHS, DPT; and Pradeep Rapalli, PT, DPT


Clinical Practice Guideline Physical Therapy Evaluation and Treatment After Concussion/Mild Traumatic Brain Injury

Journal of Orthopedic & Sports Physical Therapy; April 2020; Volume 50, Issue 4





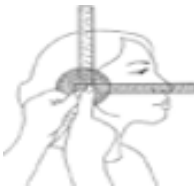




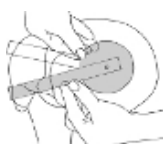
This is for informational and educational purposes only. It does not constitute and should not be used as a substitute for medical advice, diagnosis, rehabilitation, or treatment. Patients and other members of the general public should always seek the advice of a qualified healthcare professional regarding personal health and medical conditions. The Academy of Neurologic Physical Therapy and its collaborators disclaim any liability to any party for any loss or damage by errors or omissions in this publication.

References



Active Range of Motion of the Cervical Spine

Goniometer Measurement

Cervical Movement	Range of Motion in Degrees	Goniometer Placement	Starting Position	End Position
Flexion	45	<u>Fulcrum</u> - Over the external auditory meatus <u>Stationary arm</u> - Perpendicular or parallel to the ground <u>Movement arm</u> - With base of nares or parallel to longitudinal axis of tongue depressor		
Extension	45	<u>Fulcrum</u> - Over the external auditory meatus <u>Stationary arm</u> - Perpendicular or parallel to ground <u>Movement arm</u> - With base of nares or parallel to longitudinal axis of tongue depressor		
Lateral Flexion	45	<u>Fulcrum</u> - Over spinous process of C7 <u>Stationary arm</u> - Spinous processes of thoracic vertebrae so that arm is perpendicular to ground <u>Movement arm</u> - Dorsal midline of head. Reference occipital protuberance		
Rotation	60	<u>Fulcrum</u> - Over center of cranial aspect of head <u>Stationary arm</u> - Parallel to imaginary line between the two acromial processes <u>Movement arm</u> - With the tip of the nose		


ANPT

Concussion/mTBI Knowledge Translation Task force

Handout Created by:
Naseem Chatiwala, PT, DPT, MS; Annie Fangman, PT, DPT; Michelle Gutierrez, PT, DSc; John Heick, PT, DPT, PhD; Ethan Hood, PT, DPT, MBA; Victoria Kochick, PT, DPT; Becky Bliss, PT, DHSc, DPT; and Pradeep Rapalli, PT, DPT


Clinical Practice Guideline Physical Therapy Evaluation and Treatment After Concussion/Mild Traumatic Brain Injury

Journal of Orthopedic & Sports Physical Therapy; April 2020; Volume 50, Issue 4



This is for informational and educational purposes only. It does not constitute and should not be used as a substitute for medical advice, diagnosis, rehabilitation, or treatment. Patients and other members of the general public should always seek the advice of a qualified healthcare professional regarding personal health and medical conditions. The Academy of Neurologic Physical Therapy and its collaborators disclaim any liability to any party for any loss or damage by errors or omissions in this publication.

References



Active Range of Motion of the Cervical Spine

Tape Measurement

Client position

Place the individual in the sitting position, with the thoracic and lumbar spine well supported by the back of a chair. Feet should be flat on the floor, shoulders should be relaxed, and hands should rest on the thighs. Position the cervical spine in 0 degrees of rotation and lateral flexion.

Stabilization

Stabilize the shoulder girdle and chest to prevent extension of the thoracic and lumbar spine. Usually, the stabilization is achieved through the cooperation of the individual and support from the back of the chair.

Measurement

Difference between initial and final measurements is the ROM. Record patient's ROM in centimeters

Cervical Movement	Landmarks	Mean Measurement Value
Flexion	From tip of the mandible (0cm) to Sternal notch	1.0 to 4.3 cm
Extension	From tip of the mandible (0cm) to sternal notch	18.5 to 22.4 cm
Lateral Flexion	From acromion process to lowest point of ear lobe	11 to 13 cm
Rotation	From tip of the mandible to acromion process	11.0 to 13.2 cm

ANPT


Concussion/mTBI Knowledge Translation Task force

Handout Created by:

Naseem Chatiwala, PT, DPT, MS; Annie Fangman, PT, DPT; Michelle Gutierrez, PT, DSc; John Heick, PT, DPT, PhD; Ethan Hood, PT, DPT, MBA; Victoria Kochick, PT, DPT; Becky Bliss, PT, DHS, DPT; and Pradeep Rapalli, PT, DPT

Clinical Practice Guideline Physical Therapy Evaluation and Treatment After Concussion/Mild Traumatic Brain Injury

Journal of Orthopedic & Sports Physical Therapy; April 2020; Volume 50, Issue 4



This is for informational and educational purposes only. It does not constitute and should not be used as a substitute for medical advice, diagnosis, rehabilitation, or treatment. Patients and other members of the general public should always seek the advice of a qualified healthcare professional regarding personal health and medical conditions. The Academy of Neurologic Physical Therapy and its collaborators disclaim any liability to any party for any loss or damage by errors or omissions in this publication.

References

